

The Diagnosis of Macular Edema in Color Fundus Images Using Image Processing

Devashree R.Patrikar¹, Dhanashree Pannase²

¹(Electronics & communication, Priyadarshini/ RTMNU Nagpur, India)

²(Electronics & telecommunication, Atharva/ Mumbai, India)

Abstract: The leading cause of blindness in the western working age population and micro aneurysms is Diabetic retinopathy. In Diabetic retinopathy (DR) the blood vessels of the retina of the human eye get damaged which affects the vision. Diabetes causes very high amount of glucose to flow through the blood vessels resulting in its damage. If these blood vessels are present near the macula region i.e. the central region of the eye it affects the vision. As the amount of glucose increase, the blood vessels leak fluid onto the macula leading to its swelling which blurs the vision eventually leading to complete loss of vision. This paper is based on the detection of the eyes having normal vision from the eyes affected by Macular Edema. Here the images of the eyes having normal vision are compared with the images of the eyes that are affected with Macular Edema. The method of Rotational Asymmetry is used to identify the Macular Edema affected images. If the image is edema affected it also states its severity of the disease using Computer Aided Diagnosis. To capture the global characteristics of the fundus images and discriminate the normal from DME images a feature extraction technique is introduced.

Keywords: Abnormality detection, diabetic macular edema, hard exudates.

I. Introduction

Diabetes is a disease in which blood sugar, levels are too high. Glucose comes from the foods that a person eats. Insulin is a hormone that helps the glucose get into the body cells to give them energy. With 'type 1' diabetes, a person's body does not make insulin. The effect of high sugar in one's body can pose threat to the organs. The organs that are primarily affect in human body are heart, blood vessels, nerves, eyes and kidneys.

A person who has high diabetes is prone to Diabetic Retinopathy. Diabetic retinopathy is one of the most common complications of diabetes. It usually affects both eyes. People suffering from this disease have to suffer with damaged blood vessels in their retina which is the light-sensitive layer at the back of the eyes.

In the Western working age population Diabetic retinopathy is the leading cause of blindness. In diabetes extensive amount of glucose runs in the blood stream in the blood vessels. The blood vessels are not capable of handling such large amount of glucose, thus they might get damaged. The blood vessels in the eye are very sensitive to such large variations in the presence of glucose in the blood stream. Resulting in the damage of blood vessels.

During the initial stage, such type of complication is called Non-Proliferative Diabetic Retinopathy (NDPR).

If the glucose tend to rise further the blood capillaries burst, resulting in the abnormal leakage and accumulation of fluid from damaged blood vessels in the nearby region of retina called Macula. This condition called Macular Edema. There is a formation of Hard Exudates due to the secretion of plasma from the capillaries.

As the disease progresses, Non-Proliferative Diabetic Retinopathy (NDPR) enters advanced stage. The blood vessels now start bleeding resulting into cloud vision and destroy the retina leading to complete loss of vision. The evaluation of the severity of the risk of edema is done based on the proximity of the hard exudates to the macula, which means how near the Hard Exudates are present in the macula. Macula is defined to be a circular region centred at the fovea and which has one optic disc diameter. The risk of Diabetic Macular Edema rises when the Hard Exudates locations approach near the macula. For the prevention of this disease the detection of the presence of HE is extremely important.

The method that is used for the detection of this disease is screening. Screening can save eyesight. Screening involves manual procedures but they might also result in errors. For the purpose of detection of Macular Edema, the location of macular region in the fundus image is very important. Macula is the region which is near the centre of the eye. Early Treatment Diabetic Retinopathy Studies (ETDRS) grading scale is used to mark the regions of macula. The important step in the assessment of retinal images for pathologies is detection of the fovea. Optical Disc Detection method is used as a starting point. In the case of normal retina images, the fovea is the darkest spot inside macular region and morphological operations make it more visible

than its macula background. The abnormalities in the region i.e. the presence of hard exudates are observed once the macular region is detected.

II. Objective Of The Present Work

Macula is defined to be a circular region centred at the fovea and with one optic disc diameter. The proximity of the hard exudates to the macula determines the severity of the risk of edema. When the HE locations approach the macula, the risk of Diabetic Macular Edema rises. Thus it is very important to detect the presence Hard Exudates on the fundus image. If the HE is present near the Macula, then there is a risk of Diabetic Macular Edema. If the hard exudates are present then the severity of the disease can also be determined depending upon how near the HE are from the Macula. So it is very important to properly and accurately diagnose the disease so that proper treatment can be given to the patient accordingly. The processes of diagnosing patients having diabetes are categorized as follows.

Firstly a traditional healthcare performed is performed through primary, secondary and tertiary care. The patients initially arrive at the primary care centers with health problems and if their health requires more care they are referred for advanced care to secondary and further moved to tertiary care providers. This mode of health care is collectively referred to as primary care. The second approach to healthcare is disease screening to prevent diseases and prolong life in population. For example, screening for diseases like cataract and diabetic retinopathy is being adopted as it impacts several people with vision impairment. Computer Aided Diagnosis (CAD) in both the healthcare scenarios can reduce the time and effort spent on diagnosis when compared to manual assessment.

2.1 COMPUTER-AIDED DIAGNOSIS SYSTEM FOR DIABETIC RETINOPATHY SCREENING

The system that assists doctors in the interpretation of medical images is called Computer Aided Diagnosis. Computer Aided Diagnosis (CAD) is a technology which combines the elements of computer vision technology and artificial intelligence and with radiological and pathology image processing. The proposed system of CAD consists of various modules responsible for the following tasks:

2.1.1 Pre-processing

Pre-processing involves unwanted distortion suppression and it enhances the images resulting in improved quality of the image. Before finding anatomic landmarks and lesions within the image, angular extent which is called as the field of view (FOV) is detected. The image is then resized so that the FOV of the image is standardized diameter of 650 pixels independent of the image resolution.

2.1.2 Quality Verification

This module determines the quality level of the image. There are a few assumptions while determining the quality level of the image that an image of sufficient quality should contain particular image structures—namely, the vasculature, the optic disc (OD), and the background, according to a certain predefined distribution. A Gaussian filter bank (GFB) is applied to the image and the outputs are clustered. One cluster represents one structure. With one level per cluster a histogram of the image is structured. As the image is a coloured image, histograms of the R, G, and B color planes features a support vector machine trained to assess the image quality. The output of this module is a probability indicating the likelihood the quality of the image is normal. It should be noted that the output of this module only to analyze the quality level and not to discard images of low quality.

2.1.3 Vessel Segmentation

The vessel segmentation is one of the most important anatomic structures in retinal images. To distinguish small vessels from red lesions and as an aid for the identification of other anatomic landmarks, such as the OD vessel segmentation is necessary. By means of pixel classification using GFB features and a supervised classifier a pixel probability map indicating the likelihood that the pixel belongs to a vessel is obtained as output

2.1.4 OD Detection

Another important anatomic structure is the OD Detection. It is necessary to identify this element so as to prevent erroneously detected bright lesions within the OD. The OD is identified as the calculation of regression rule between its center location and a group of features based on intensity, vessel orientation, and density. The output of the module is a location which is within the image which has the highest probability that it is the OD center.

2.1.5 Red Lesion Detection

The important signs of DR and their detection are Red lesions, comprising micro aneurysms and vascular abnormalities and these are therefore of paramount importance for a DR screening system. By using a hybrid approach based on mathematical morphology, specifically designed for smaller candidates, potential red lesion locations are identified and a supervised pixel classification is performed using GFB features, for the detection of larger red lesions. The detected candidates which are detected with lesions are then assigned a probability of how intense a red lesion is. This is done using a supervised classifier and a group of features describing the candidate shape, structure, color, and contrast.

2.1.6 Bright Lesion Detection

In a group of people having DR positive screening bright lesions, such as exudates, cotton wool spots, or drusen, are frequently encountered. As soon as red lesions are detected, a supervised pixel classification is first performed to obtain candidates suffering from brighter red lesions. There probability that the red lesion may not be a case of Macular Edema. In order to make the diagnosis correct the method of supervised classification is done using a group of candidate features, such as shape, color, contrast and distance to the nearest red lesion. The outputs of the different modules used in the project must be combined to obtain a final decision about the patient's diagnosis. Now, a group of features based on the diverse outputs of the aforementioned modules are calculated which include quality likelihood or the highest likelihood of red or bright lesions in the examination. These features are given as input to a nearest neighbor called as the k nearest-neighbor (kNN) classifier. This classifier was trained on an independent training set and is not used for any other purpose in this research. In the output of this classifier, a per-examination probability is determined indicating the likelihood that the examination would be referred to an ophthalmologist.

2.1.7 ROTATIONAL SYMMETRY

In this paper, the color fundus images which are under observation will be compared with the reference image. This reference image will be the ideal image of a clear eye. The image under observation will be taken from the database that will be acquired from the ophthalmologist. Database will purposely have actual defective eye images taken by color fundus camera. By using the method of rotational symmetry the image which is under observation will be compared with the reference image. Both the images, the image under observation and the reference image will be compared with each other. Both the images are compared and if they are found to be the same then the eye is not defective. If the spots are observed in the macular region then the eye is defective and the person is suffering from Macular edema. The intensity of the disease will be also detected if the red lesions are present near the macula.

2.1.8 COLOR FUNDUS IMAGE MECHANISM

One of the critical steps in the development of automated screening systems for diabetic retinopathy is the robust detection of red lesions in digital color fundus photographs. The people suffering from diabetic retinopathy (DR), an enlargement of foveal avascular zone (FAZ) is usually found in eyes resulting from a damage of capillaries. Currently it is difficult to measure FAZ enlargement in the fovea in an objective manner based on raw color fundus images. For the grading of DR severity ophthalmologists observe and record the occurrences of DR pathologies. Several challenges are faced by fundus image analysis such as improper illumination, high image variability, and artifacts due differing imaging conditions for the same patient.

2.1.9 COMPUTER-AIDED DIAGNOSIS

Computer aided diagnosis (CAD) are modern technological systems that assist doctors in the interpretation of medical images. In CAD systems, digital images are processed for typical appearances and to highlight conspicuous sections, such as possible diseases. This is done in order to offer input to support a decision taken by the professional.

One of the major research subjects in medical imaging and diagnostic radiology is Computer-aided diagnosis (CAD). In this paper, the philosophy for early development of Macular Edema, CAD schemes are presented together with the current status and future potential of CAD. Radiologists use the computer output as a "second opinion" using CAD and make the final decisions. CAD is a concept which is established by taking into account equally the roles of physicians and computers. Whereas automated computer aided diagnosis is a concept based on computer algorithms only. With the implementation of CAD, the performance by computers does not have to be comparable to or better than that by physicians, but needs to be complementary and helpful to that by physicians. The early detection of breast cancers on mammograms, retina scans have been helpful for assisting physicians using CAD scheme. As vertebral fractures can be detected reliably by computer on lateral chest radiographs, the radiologists accurately detect vertebral fractures by the use of CAD, and thus early diagnosis of osteoporosis would become possible. Thus in various fields of medicine, CAD system can be useful

for early detection of diseases. A CAD system has been developed for assisting radiologists in the detection of defective bones as well. Thus CAD proves to be a very important and proves to be a useful tool for helping doctors from various fields and help patients suffering from different ailments.

III. Work Plan And Methodology

The main aim of the project is to determine the presence of hard exudates in the image. For this purpose we are comparing the edema affected fundus image with the normal fundus image. This is done using the motion pattern recognition.

The process of classification of input data into objects or classes based on some key features is called the process of pattern recognition. The main aim is compare the pattern of a test image with the reference image.

We are looking for any presence of Hard Exudates. If HE is absent there is a smooth rotational symmetry about the Macula. If HE are present there is a rough rotational symmetry about the macula. It means that a person is suffering from macular edema.

This methodology also has the capability that if a person is suffering from Macular Edema the severity of the disease can also be determined. This can be done by observing the nature of Hard Exudates using motion pattern recognition.

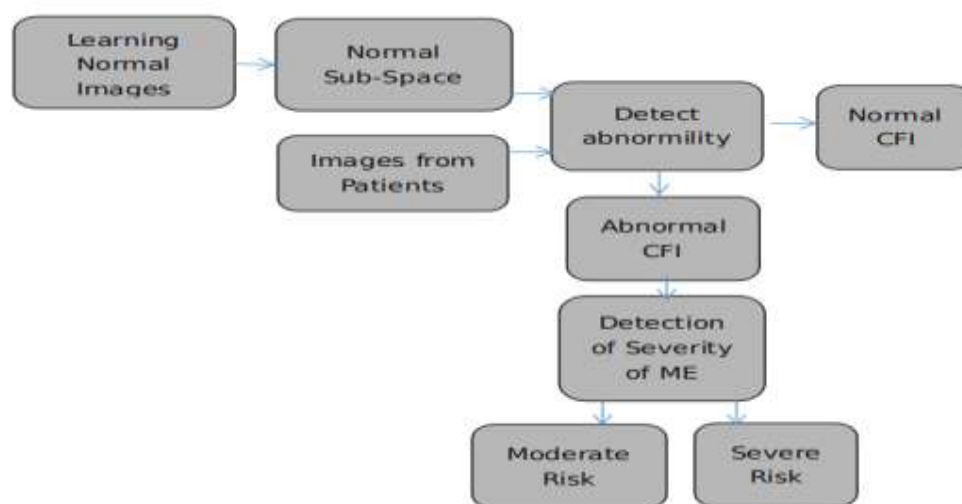


Fig. Method for detection and assessment of HE in Fundus Images

CAD systems have always provided upper hand in diagnosing diseases. Some diseases are life threatening. CAD systems provide a technique to scan multiple images and to analyze them in bulk. Even the smallest of lesions are detected using CAD. In this paper the rotational symmetry technique is used analyze multiple images. It effectively detects the lesions. If the lesions in the form of Hard Exudates are present near the Macula region then the patient is severely suffering from Macular Edema and necessary action must be taken so as to avoid further loss. CAD compares the affected image from the clear ones. Thus it helps the ophthalmologists to take necessary action and help the patient recover soon.

IV. Conclusion

Screening of mass patients for a disease using images is a challenging problem. There are several barriers in the form of social, operational, educational issues integral to the disease screening. These affect the nature of computer aided diagnosis. The challenges in image based disease screening have been identified. These challenges are pertaining to a popular disease screening problems retinal diseases from color fundus images and. There is scope of future work in different avenues. The future scope includes breast cancer detection from digital mammograms. The proposed hierarchical approach has been evaluated and performed on several image datasets and improvement in the disease detection performance is observed against the traditional detection methods. Further analysis is required regarding the new approach in a screening setup to identify the operational challenges in its implementation.

References

- [1]. W. Huan, H. Wynne, and L. M. Li, "Effective detection of retinal ex- udates in fundus images," in Proc. 2nd Int. Conf. Biomed. Eng. In- format., Oct. 2009, pp. 1–5.
- [2]. K. Sai Deepak, Jaynath Sivaswamy, 'Automatic assessment of macular edema from color retinal images' IEEE transactions on Medical imaging, vol 31, no. 3, March 2012.
- [3]. Giancardo, L. ; Meriaudeau, F. ; Karnowski, T.P. ; Li, Y. ; Tobin, K.W. ; Chaum, E. 'Automatic retina exudates segmentation without a manually labelled training set' 2011 , Page(s): 1396 - 1400
- [4]. Eadgahi, M.G.F. ; Pourreza, H. 'Localization of hard exudates in retinal fundus image by mathematical morphology operations' Computer and Knowledge Engineering (ICCKE) 2012 , Page(s): 185 - 189
- [5]. Aftab, U. ; Akram, M.U.'Automated identification of exudates for detection of macular edema' Biomedical Engineering Conference (CIBEC), 2012 Cairo International, 2012 , Page(s): 27 – 30
- [6]. Ziyang Liang ; Wong, D.W.K. ; Jiang Liu ; Ngan-Meng Tan ; Xiangang Cheng ; Cheung, G.C.M. ; Bhargava, M. ; Tien Yin Wong 'Automatic fovea detection in retinal fundus images' Industrial Electronics and Applications (ICIEA) 2012 , Page(s): 1746 – 1750
- [7]. Medhi, J.P. ; Nath, M.K. ; Dandapat, S. 'Automatic grading of macular degeneration from color fundus images' Information and Communication Technologies (WICT) 2012 , Page(s): 511 - 514
- [8]. Asim, K.M. ; Basit, A. ; Jalil, A. 'Detection and localization of fovea in human retinal fundus images' Emerging Technologies (ICET) 2012 , Page(s): 1 – 5
- [9]. Giancardo, L. ; Meriaudeau, F. ; Karnowski, T.P. ; Tobin, K.W. ; Grisan, E. ; Favaro, P. ; Ruggeri, A. ; Chaum, E. 'Textureless Macula Swelling Detection With Multiple Retinal Fundus Images' Biomedical Engineering Volume: 58 , Issue: 3 2011 , Page(s): 795 - 799
- [10]. El-Shahawy, M.S. ; ElAntably, A. ; Fawzy, N. ; Samir, K. ; Hunter, M. ; Fahmy, A.S. 'Segmentation of Diabetic Macular Edema in fluorescein angiograms' Biomedical Imaging: From Nano to Macro 2011 , Page(s): 661 – 664
- [11]. Lim, S.T. ; Zaki, W.M.D.W. ; Hussain, A. ; Lim, S.L. ; Kusalavan, S. 'Automatic classification of diabetic macular edema in digital fundus images', Humanities, Science and Engineering (CHUSER), Page(s): 265 – 269, 2011
- [12]. R. F. N. Silberman, K. Ahlrich, and L. Subramanian, "Case for auto- mated detection of diabetic retinopathy," Proc. AAAI Artif. Intell. De- velopment (AI-D'10), pp. 85–90, Mar. 2010.
- [13]. P. C. Siddalingaswamy and K. G. Prabhu, "Automatic grading of diabetic maculopathy severity levels," in Int. Conf. Syst. Med. Biol. (ICSMB), Dec. 2010, pp. 331–334.
- [14]. Ziyang Liang ; Wong, D.W.K. ; Jiang Liu ; Ngan-Meng Tan ; Xiangang Cheng ; Cheung, G.C.M. ; Bhargava, M. ; Tien Yin Wong 'Automatic fovea detection in retinal fundus images' Digital Object Identifier, 2012 , Page(s): 1746 – 1750
- [15]. Osareh, M. Mirmehdi, B. Thomas, and R. Markham, "Automated identification of diabetic retinal exudates in digital colour images,"Br. J. Ophthalmol., vol. 87, pp. 1220–1223, Oct. 2003.
- [16]. Walter, T.; Klein, J.-C.; Massin, P. ; Erginay, A. 'A contribution of image processing to the diagnosis of diabetic retinopathy-detection of exudates in color fundus images of the human retina' Medical Imaging, 2002 , Page(s): 1236 – 1243.